



Review Article

Ustekinumab in Pediatric Dermatology: An Updated Review



Ahmed Samaouel Chehad^{1,2*} , Nada Boutrid³ and Hakim Rahmoune^{3,4}

¹Faculty of Medicine, Constantine-3 University, Constantine, Algeria; ²Department of Dermatology, University Hospital of Constantine, Constantine, Algeria; ³LMCVGN Research Laboratory; Faculty of Medicine, Setif-1 University, Setif, Algeria; ⁴Department of Pediatrics, University Hospital of Setif, Setif, Algeria

Received: May 12, 2022 | Revised: July 18, 2022 | Accepted: August 11, 2022 | Published online: September 16, 2022

Abstract

Managing chronic pediatric skin disorders is challenging due to a lack of approved medication and the relative weakness of research studies for this age group. Ustekinumab is a human monoclonal antibody that targets the p40 subunit shared by interleukin-12 and interleukin-23 and thereby modulates the inflammatory reaction triggered by the T-helper and T-helper 17 pathways, respectively. Currently, in dermatology, ustekinumab is the only interleukin-12/interleukin-23 inhibitor approved by regulatory authorities to treat moderate to severe psoriasis in adults, adolescents, and children aged six years and older. Although off-label and not supported by strong evidence, the therapeutic use of ustekinumab has been gradually extended to various other dermatoses. The reported adverse events of this biologic in pediatric patients were generally consistent with those in adults. However, its long-term safety remains to be confirmed. In this review, we discuss the existing evidence on the mechanisms of ustekinumab action, the current regulatory authority-approved indications, off-label use in pediatric cutaneous disorders, and the most reported adverse events related to this drug.

Introduction

Ustekinumab is a first-in-class anti-interleukin (IL)12/23 immunoglobulin (Ig)G1k monoclonal antibody (mAb) that modulates T-helper (Th)1 and Th17 functions. Ustekinumab was developed by Centocor Research & Development, a division of Johnson & Johnson Pharmaceutical Research and Development, LLC, using human Ig transgenic mice.¹

On January 16, 2009, the European Medicine Agency (EMA) and then on September 25, 2009, the Food and Drug Administration (FDA) approved ustekinumab in adult psoriasis based on

the PHOENIX trials.^{2,3} In October 2017 and July 2020, the FDA approved an expanded indication for adolescents (12–18 years of age) and pediatric psoriasis (6–11 years of age), respectively. The safety and efficacy of ustekinumab in the pediatric population have been evaluated in two phase-III clinical trials: CADMUS and CADMUS Jr studies.^{4,5} In adult patients, in addition to psoriasis, ustekinumab has been widely used “off-label” for a multitude of dermatologic entities, namely, pityriasis rubra pilaris (PRP), hidradenitis suppurativa (HS), pyoderma gangrenosum, mucocutaneous manifestations of Behçet disease and atopic dermatitis (AD). However, there are still many controversies regarding its efficacy and safety profile in pediatric patients. All the data available are from experience-based retrospective analyses, case reports, or small series.

In this review article, available clinical data on pediatric use of ustekinumab will be discussed for plaque psoriasis and other types of psoriasis, PRP, HS, AD, alopecia areata (AA,) and congenital ichthyosis. Additionally, we will review the dosage, administration regimens, and adverse events (AEs) associated with ustekinumab treatment.

A literature search was performed until June 2022 in PubMed using the terms ‘ustekinumab’, ‘IL12/23 inhibitors’, ‘IL12/IL23 inhibitors’, ‘pediatric’, ‘psoriasis’, ‘hidradenitis suppurativa’, ‘pityriasis rubra pilaris’, ‘atopic dermatitis’, ‘alopecia areata’, and ‘congenital ichthyosis’. In addition, all studies assessing at least one pediatric patient using ustekinumab were included.

Keywords: Ustekinumab; IL12; IL23; IL 12/IL 23 inhibitor; Biologic therapy.

Abbreviations: AA, alopecia areata; AD, atopic dermatitis; AEs, adverse events; DITRA, Deficiency of the Interleukin-36 Receptor Antagonist; EMA, European Medicine Agency; EPP, erythrodermic pediatric psoriasis; FDA, Food and Drug Administration; GPP, guttate psoriasis; GWAS, genome-wide association studies; HS, hidradenitis suppurativa; IFN, interferon; Ig, immunoglobulin; IL, interleukin; NK, natural killer; PPP, pustular pediatric psoriasis; PRP, pityriasis rubra pilaris; QoL, Quality of life; RCTs, randomized placebo-controlled trials; Th, T-helper; TNF, tumor necrosis factor.

***Correspondence to:** Ahmed Samaouel Chehad, Department of Dermatology, University Hospital of Constantine, Constantine25000, Algeria. ORCID: <https://orcid.org/0000-0003-4228-3443>. Tel: +213 661798926, Fax: +213-31-886918, E-mail: chehad_s@yahoo.fr

How to cite this article: Chehad AS, Boutrid N, Rahmoune H. Ustekinumab in Pediatric Dermatology: An Updated Review. *J Explor Res Pharmacol* 2023;8(1):66–73. doi: 10.14218/JERP.2022.00045.

Regulatory authority-approved indications for use in cutaneous disorders

As in adult patients, the only approved indication of ustekinumab in pediatric dermatology is chronic plaque psoriasis.

Psoriasis: Generalities, pathogenesis, and treatments

Psoriasis is a chronic inflammatory skin disease marked by well-defined erythematous patches and may be accompanied by systemic comorbidities.⁶ The worldwide prevalence of psoriasis is estimated to be approximately 3%, and approximately one-third of psoriasis cases develop in childhood. Although benign, the effect of psoriasis on patient quality of life (QoL) can be major, especially in children. The most common clinical type of the disease in children and adolescents is plaque psoriasis, which constitutes more than 41% of cases, whereas the less common ones include erythrodermic and pustular pediatric psoriasis (PPP).⁷ Furthermore, face involvement and guttate psoriasis (GPP) are more common than in adults, while napkin psoriasis is specifically seen in infants.

The pathogenic model leading to plaque-type psoriasis formation has evolved over the past 20 years. Thus, evidence from immunological studies and genome-wide association studies (GWAS) supports that the main inflammatory pathway involves the tumor necrosis factor α (TNF α)–IL23–Th17 axis.⁸ IL17 acts as a driver of inflammation and induces the production of cytokines (IL6, G-CSF, TNF α) and chemokines (CXCL1, CXCL2, CCL20), which recruit neutrophils and monocytes at the site of T-cell activation and lead to psoriasis-like symptom development.⁹

Pediatric psoriasis is different from adult psoriasis in its clinical manifestation, favoring the hypothesis that different pathogenic mechanisms may be involved. However, few studies have addressed this issue; most were small pilot studies. For example, KIM *et al.*¹⁰ showed that plaque-type pediatric psoriasis lesions have significantly increased TNF α and decreased IL17 levels compared with adult psoriatic patients. Although these findings were also noted in GPP, no significant difference in cytokine levels was found in pustular-type disease. In another study, Zhang *et al.*¹¹ reported that an increased number of circulating Th17 and regulatory T cells was positively correlated with disease severity in pediatric psoriasis.

Management of chronic plaque psoriasis remains challenging in children, as evidence-based recommendations are scarce. Most treatments are used off-label, and few high-quality studies are available. Thus, treatment recommendations were based primarily on guidelines for adult psoriasis, a few case series, expert opinions, or experience gained through systemic drugs in other pediatric diseases. Topical therapies are the first line of treatment for mild disease, representing most cases of childhood psoriasis. However, the more severe or recalcitrant disease is not uncommon in children, and phototherapy or systemic treatments must be discussed.

Among the multiple systemic treatments available for psoriasis in adults, only a few systemic drugs are approved for use in the pediatric population.¹² Phototherapy and conventional systemic medications, including methotrexate, ciclosporin, acitretin, and fumarates, are used to treat moderate to severe pediatric psoriasis. Although these therapies benefited some patients with pediatric psoriasis, they had limited efficacy and the potential for AEs. Therefore, a better understanding of the pathophysiology of psoriasis has led to the development of biologics that selectively target cytokines implicated in the disease pathogenesis. Thus, biologic agents licensed for the treatment of pediatric psoriasis are

two TNF α inhibitors (etanercept and adalimumab) approved for four years and older,¹³ one IL12/IL23 inhibitor (ustekinumab), and one anti-IL17 blocker (ixekizumab) that are both approved for the treatment of psoriasis six years and older.^{14,15}

Action mechanism of ustekinumab in psoriasis

Ustekinumab is a first-in-class therapeutic human IgG1 κ mAb that binds to the p40 subunit. It disrupts the interaction of IL12 and IL23 with their shared cell-surface receptor, IL12R β 1, thereby neutralizing their biological activities. However, this mAb cannot bind to endogenous IL12 or IL23 that are already bound to receptor complexes and is unlikely to mediate Fc effector functions, such as complement-dependent cytotoxicity or antibody-dependent cellular cytotoxicity.¹

IL12 is a heterodimeric molecule comprising two subunits, p35 and p40, while IL23 has a similar structure composed of p19 and p40 subunits. Both cytokines are predominantly generated by innate immune cells in response to microbial stimulation. IL12 binds to its receptor (IL12R β 1/IL12R β 2) expressed by activated natural killer (NK) cells and naive CD4+ T cells that induce their differentiation into Th1 mature lymphocytes, which in turn increases the secretion of interferon (IFN) γ . The binding of IL23 to its receptor (IL12R β 1/IL23R) stimulates another CD4+ T-cell subset (Th17) to produce type 17 cytokines, such as IL17, IL22, and GM-CSF.^{1,16,17} Within the skin, overactivated IL12 and IL23 signaling drives aberrant Th1 and Th17 immune responses and promotes the formation of psoriasis plaques.¹⁸

Figure 1 synthesizes the pathophysiology of psoriasis and the ustekinumab mechanism of action.

Ustekinumab approval trials in pediatric plaque psoriasis

The approval of ustekinumab in adult patients (age \geq 18 years) is based on data from the PHOENIX 1/2^{2,3} and ACCEPT trials,¹⁹ which show that this biologic has a better efficacy and safety profile than earlier anti-TNF α agents. Later, in October 2017, the FDA approved an expanded indication for adolescents (age \geq 12 to $<$ 18 years) and for children (age \geq 6 to $<$ 11 years) in July 2020. In addition, the safety and efficacy of ustekinumab in the pediatric population have been evaluated in two phase-III clinical trials: CADMUS (double-blind, placebo-controlled study) and CADMUS Jr (open-label, single-arm study).

A total of 154 participants with moderate to severe psoriasis were enrolled in the two studies (110 adolescents in the CADAMUS trial and 44 children in the CADAMUS Jr trial). A weight-based dose of ustekinumab ($<$ 60 kg: 075 mg/kg; \geq 60 to \leq 100 kg: 45 mg; $>$ 100 kg: 90 mg) was administered by subcutaneous injection at weeks 0 and 4, followed by an injection every 12 weeks, led to PASI 75 and PASI 90 responses in more than 80% and 60% of patients, respectively. Not only was the response well maintained through week 52 in both trials, but the AEs and serious AEs in CADAMUS trials were also similar between the ustekinumab and placebo groups and were consistent with those previously observed in adult studies.

Effectiveness in pediatric patients has been confirmed in other studies. For example, a recent, multicentre retrospective study was conducted in France and Italy that enrolled children under 12 years of age with psoriasis who received biological agents, including ustekinumab.²⁰ Ustekinumab was associated with a significant decrease in PASI score from 11.6 ± 8.3 at baseline to 2.6 ± 2.2

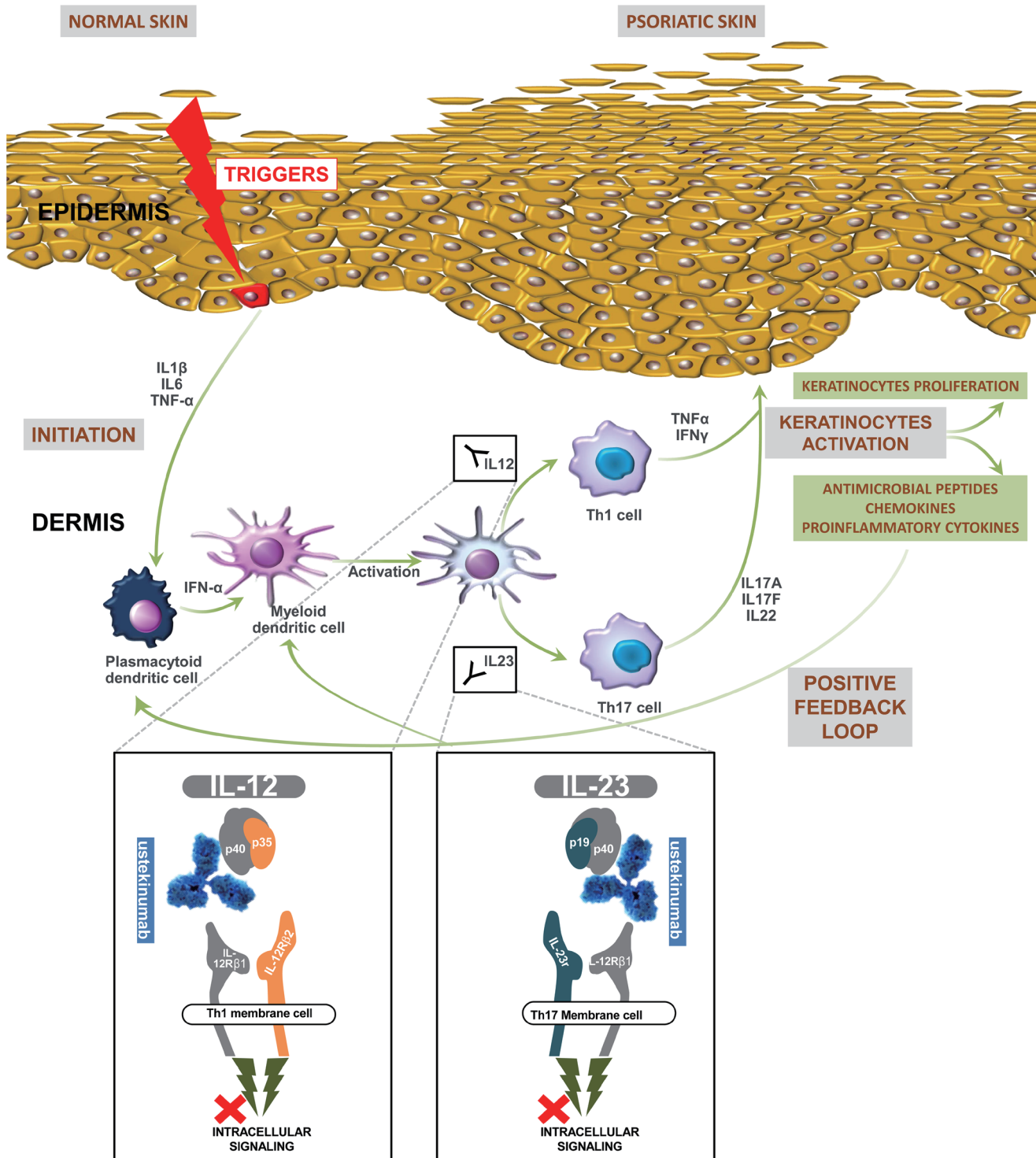


Fig. 1. Current concepts in psoriasis pathophysiology and ustekinumab mechanism of action. In response to several external triggers, activated keratinocytes release proinflammatory cytokines that recruit and activate plasmacytoid dendritic cells to produce large amounts of IFN α . This cytokine induces phenotypical and functional maturation of myeloid dendritic cells into fully activated antigen-presenting dendritic cells, thereby promoting the expansion and differentiation of autoreactive T cells through antigen presentation and secretion of cytokines, mainly IL12 and IL23. The former is implicated in Th1 expansion, and the latter provides Th17 lymphocyte differentiation. The activated lymphocytes secrete TNF α , IFN γ , IL17, and IL22 that stimulate keratinocytes to proliferate and produce antimicrobial peptides, chemokines, and proinflammatory cytokines, which further activate dendritic cells, creating a positive feedback loop. Ustekinumab is a mAb that binds to the p40 subunit shared by IL12 and IL23 and disrupts the interaction of these cytokines with a shared cell-surface receptor chain, IL12R β 1. IFN α , interferon-alpha; IL, interleukin; IL12R β 1, interleukin-12 receptor beta 1; IFN γ , interferon-gamma; mAb, monoclonal antibody; Th, t-helper; TNF α , tumor necrosis factor-alpha.

after three months and was maintained over two years. Another recent study from a multicenter real-life study²¹ that evaluated the drug survival rates of biologics in French psoriatic patients showed that ustekinumab remains an effective and valid therapeutic option whether the agent was given as a first-line or second-line biologic. Ladha *et al.*²² reported that 78.3%, 69.9%, and 47.8% of ustekinumab-treated patients achieved PASI 75, PASI 90, and PASI 100, respectively, at week 16, with responses maintained at week 52.

Off-label uses of ustekinumab in cutaneous disorders

Despite a further lack of approval, IL12/IL23 blockers have been used successfully for many dermatologic conditions in pediatric populations. Unfortunately, the most available literature is limited to small case series, and case reports, therefore, cannot produce reliable evidence about the efficacy and safety of these biologic agents. For this reason, ustekinumab should be reserved for severe and recalcitrant cases of pediatric dermatoses that fail or do not tolerate first-line treatment and for which alternative treatment options are lacking.

Ustekinumab for other subtypes of pediatric psoriasis

Other forms of pediatric psoriasis include GPP and the least common types: erythrodermic pediatric psoriasis (EPP) and PPP.²³

GPP is a form of acute psoriasis that often follows infections, most commonly streptococcal upper respiratory tract infections but also viral infections, including SARS-CoV-2. GPP is manifested by the eruption of several small (0.5–1 cm) “drop-like” papules widely distributed throughout the skin. Often, the eruption clears within 3–4 months, but many patients experience recurrence or evolve into chronic plaque psoriasis.^{24,25} Although GPP is the second-most common type of psoriasis seen in children (14 to 30%),²⁶ the success of ustekinumab in the treatment of recalcitrant guttate psoriasis has been studied in only a few published cases in adults. However, no reports have been documented in children.

EPP is the rarest form of psoriasis in children and is associated with morbidity and potential mortality. It typically presents with generalized inflammatory erythema involving at least 75% of the body surface area. Treatment of EPP is challenging due to its rarity, the lack of randomized controlled trials, and the absence of standardized guidelines. In addition, evidence supporting the role of biological agents in treating EPP is lacking.²⁷ Nevertheless, successful use of ustekinumab has been described for rare cases of EPP in children. Signa *et al.*²⁸ described two 7-year-old dizygotic twins with a history of severe erythrodermic psoriasis related to CARD14 mutations with poor clinical response to topical and systemic therapy, including steroids, retinoids, cyclosporine, and etanercept. Administration of ustekinumab (2 mg/kg every eight weeks) allowed a complete resolution of skin lesions without any severe AEs, with a long-term follow-up.

Pustular psoriasis (PP) is an uncommon form of the disease, which accounts for up to 13.1% of all childhood psoriasis.²⁹ PP is characterized by superficial pustules on a background of erythema and is subdivided into three subgroups based on their presentations, i.e., generalized PP, acrodermatitis continua of Hallopeau, and palmoplantar pustulosis. Treatment guidelines have been established for PP, but no controlled studies are available yet for PPP. Although the Medical Board of the National Psoriasis Foundation recommended acitretin, cyclosporine, etanercept, or methotrexate as the first-line therapeutic options in children

with the generalized form of PPP,³⁰ infliximab (TNF α blocker) is the biologic that is usually preferred due to its rapid onset of action. It has been postulated that pustule formation is caused by an increase in some inflammatory mediators, such as IL17F and IL8, which are good targets for ustekinumab. However, the efficacy of ustekinumab in PPP has been highlighted in only a handful of case reports. Thereby, Herlin *et al.*³¹ showed that ustekinumab was effective in generalized PP at 0.9 mg/kg every nine weeks, with sustained remissions lasting up to 48 months after the initiation of biologic therapy. Likewise, another case in a pre-schooler female with a de novo mutation in caspase recruitment domain-containing protein 14 showed notable improvement after ustekinumab treatment.³²

Ustekinumab for juvenile pityriasis rubra pilaris

PRP is a rare papulosquamous disorder classified into six groups according to clinical appearance, age of onset, and prognosis.³³ Although the etiology of PRP remains unknown, biological agents have been proven successful in recalcitrant cases, supporting the immunologic pathogenesis theory. Craiglow *et al.*³⁴ reported a case series of 15 subjects (adults and children) with CARD14-associated papulosquamous eruption that displayed characteristics of both psoriasis and PRP. Interestingly, the authors mentioned a marked clinical improvement in five of six subjects treated with ustekinumab after the failure of other systemic therapies. Although all six subjects had the onset of their disease at or before two years of age, their ages at the beginning of biological treatment have not been specified. The use of ustekinumab in the treatment of juvenile PRP has also been reported in a 7-year-old Asian girl; complete clearance was reported after one year of therapy.³⁵

Ustekinumab for hidradenitis suppurative

HS is a chronic, inflammatory, recurrent, and debilitating skin follicular disease that occurs in the apocrine gland-bearing areas of the body, most commonly the axillary, inguinal, and anogenital regions.³⁶ While many treatment options exist, no single approach is consistently successful for every patient. It has been reported that both TNF α and IL17 are increased in HS skin lesions.³⁷ Adalimumab is the only biologic therapy approved for treating HS in the pediatric population. However, treatment failure is common and needs to be considered when using other biologics, including those targeting the IL23/IL17 axis, such as ustekinumab. Provini *et al.*³⁸ reported a case of a 17-year-old girl with severe and recalcitrant HS successfully treated with a combination of high-dose ustekinumab and hyperbaric oxygen therapy. Additionally, Monsalvez *et al.*³⁹ published a similar age and gender patient with HS and ulcerative colitis controlled with ustekinumab according to Chron's disease dosage plus sulfone 50 mg daily.

Ustekinumab for atopic dermatitis

AD is the most common chronic inflammatory dermatologic disorder in the younger population, affecting almost up to 15.5% of children.⁴⁰ AD pathogenesis is multifactorial, resulting from an altered skin barrier and immune dysregulation. Most children with AD present with mild disease (67%), and the remaining 33% present with moderate to severe AD.⁴¹

Severe forms may warrant systemic treatment with traditional

systemic medications, small molecule inhibitors, or biological agents. However, available biologic options for pediatric AD remain limited. While dupilumab, a mAb that inhibits IL4 and IL13 signaling, is the only approved biologic in childhood AD, many cases remain refractory to this therapy and require off-label medications. Several successful cases have been reported in treating patients with refractory AD with ustekinumab. A proposed mechanism by which this drug exerts its effects in AD is inhibiting the Th17 pathway and its associated cytokines, IL17 and IL22, which are overexpressed in AD.⁴² All published cases have concerned adults, except two in adolescents. Agusti-Mejias *et al.*⁴³ presented a case of a 16-year-old patient who was completely cured without any AE. Wlodek *et al.*⁴⁴ reported another case of a 13-year-old girl partially recovered by ustekinumab. She experienced flares 3–4 weeks before the next injection. In contrast, randomized placebo-controlled trials (RCTs) concerning this IL12/IL23 blocker have not been able to demonstrate a benefit compared to placebo.⁴⁵

Ustekinumab for alopecia areata

AA is a common autoimmune disease that results in nonscarring hair loss. The use of traditional drugs for AA is limited by their AEs and inconsistent efficiency, especially in a pediatric population. Nevertheless, the discovery of the role of Th1, Th2, and Th17 cells in the pathogenesis of AA provides the rationale to consider IL12/IL23 blockers in recalcitrant cases.⁴⁶ However, only one case series of three pediatric patients has documented hair regrowth with ustekinumab use,⁴⁷ in contrast with several reports showing that new-onset AA occurred after this drug administration.⁴⁸

Miscellaneous

Ustekinumab has been used to treat various skin conditions such as DITRA (Erythrodermic pediatric psoriasis) and congenital ichthyosis. To date, ustekinumab has been used successfully in three children reported in two separate publications.^{49,50} All these patients presented a severe DITRA resisting multiple therapies in whom the use of ustekinumab led to an excellent clinical response, despite the need for high doses to ensure adequate control. As DITRA is an auto-inflammatory disorder, the excellent response to treatment that targets adaptive immunity reflects the complex interactions between the innate and adaptive immune systems in this disease.

Additionally, three different reports have shown the beneficial effects of ustekinumab in congenital ichthyosis. Poulton *et al.*⁵¹ describe a pediatric case of autosomal recessive congenital ichthyosis due to homozygous variants in NIPAL4 that was dramatically improved with high doses of ustekinumab after failing to respond to methotrexate and adalimumab. Volc *et al.*⁵² reported a case of Netherton syndrome in a 15-year-old girl who substantially responded after four weeks of 0.75 mg/kg ustekinumab. No signs of relapse were detected after one year of follow-up. The third report⁵³ describes two cases of ichthyosis linked to desmoplakin mutation causing erythroderma and other cutaneous and visceral abnormalities. The two patients failed to respond to multiple courses of immunosuppressants and retinoids. Based on the discovery of Th1 and Th17/IL23 skewing in the skin and Th17/IL22 skewing in blood, although performed only in one child, ustekinumab therapy was initiated in both children. After one year of biological treatment, both children showed a substantial improvement in their clinical condition and a better quality of life.

Adverse events observed with ustekinumab

Considering the relative paucity of literature on the use of ustekinumab in childhood skin diseases, much of the safety data has been taken from studies on its use in adults and other nondermatological indications. However, the available literature on the use of this drug in the pediatric population suggests that it is safe, although there is an urgent need to generate more safety data in this age group.⁵⁴

Although targeting two major cytokine pathways, AEs associated with ustekinumab use were generally nonserious, occasional, and did not lead to drug discontinuation.⁵⁵ Thus, IL17 is essential for host defense against bacterial and fungal pathogens. However, despite a decrease in IL17 signaling due to ustekinumab treatment, the infectious risk due to ustekinumab seems to be low in clinical trials. Furthermore, analysis of published register-based studies for ustekinumab did not show increased incidences of serious infections, including tuberculosis, when comparing ustekinumab to anti-TNF agents or conventional systemic therapies.^{56,57}

CADMUS trials have greatly expanded the available safety data in pediatric patients, as they have been monitored for AEs for at least one year. The AEs in this trial were consistent with those previously observed in adult patients receiving ustekinumab. In phase 3 CADMUS study⁴ in adolescents with psoriasis, the most common AEs from ustekinumab were nasopharyngitis (34.5%), upper respiratory tract infection (12.7%), and pharyngitis (8.2%). Overall, six severe AEs were reported: one worsening of psoriasis, transient leukopenia, pyelonephritis, ear infection, allergic contact dermatitis from hair dye, and one death from a motor vehicle accident. Importantly, through week 60, there were no reports of malignancies, opportunistic infections, active TB, anaphylaxis, or serum-sickness-like reactions. No new safety concerns were identified in the CADMUS Jr study,⁵ which evaluated ustekinumab in children ≥ 6 to <12 years of age.

Although uncommon, various other cutaneous and systemic AEs related to ustekinumab are well documented in the literature. Among these AEs, many immune-mediated skin diseases, such as paradoxical psoriasis, vitiligo, alopecia areata, and atopic dermatitis, have been attributed to the use of this biologic in adults as well as in the pediatric population.

The most reported skin and systemic AEs are summarized in Tables 1 and 2 for all ustekinumab indications.

Future directions

Ustekinumab should be considered if not otherwise contraindicated in severe recalcitrant diseases such as PRP, HS, and DA as well as several other dermatologic disorders despite very few sufficiently powered clinical trials evaluating ustekinumab in these off-label conditions. In addition, the recommended dosage regimen is appropriate for most patients, significantly improving compliance and quality of life, especially for pediatric patients. Thus, after two initial loading doses, children only need four doses a year, which makes it an ideal candidate for chronic childhood disorders that often require lifelong treatment.

Conclusions

Over the past two decades, the use of biological agents in the treatment of cutaneous conditions has increased worldwide. The successful use of IL12/IL23 inhibitors for the treatment of psoriasis is

Table 1. Skin adverse events associated with ustekinumab

1. Skin lesions related to the administration of treatment	Bruising, pruritus, pain, erythema, swelling, skin rash
2. Skin infections	Bacterial infections: cellulitis, mycobacterium abscessus, secondary syphilis, staphylococcal skin colonization; Viral infections: disseminated verrucae, condyloma acuminata, herpes zoster; Fungal infection: cutaneous candidiasis, Nocardia infection, disseminated sporotrichosis; Parasitic infections: plurifocal cutaneous leishmaniasis, cutaneous protothecosis
3. Skin neoplasia	Non melanoma skin tumors: basocellular carcinoma, spinocellular carcinoma; Malignant melanoma; Skin lymphomas/Lymphoproliferative disorders: Jessner-Kanof type, anaplastic large T cell lymphoma, mycosis fungoides; Multiple dermatofibromas
4. Immune mediated diseases	«de novo» psoriasis and exacerbation of prior psoriasis or psoriasis subtypes; Atopic-dermatitis and its exacerbation; Lupus-like paradoxical reaction; Alopecia areata; Skin vasculitis; Vitiligo; Dermatomyositis; Localized scleroderma (morphea); Lichen or lichenoid reaction; Frontal fibrosing alopecia; Linear IgA bullous dermatosis; bullous pemphigoid; Erythema multiforme; Erythroderma, exfoliative dermatitis and hypersensitivity reaction; Erythematous annular eruptions; Fixed drug eruption; Urticaria
5. Other skin events	Hidradenitis suppurativa; Seborrheic keratosis; Thrombotic thrombocytopenic purpura; Sarcoidosis-like paradoxical reaction; Wells syndrome; Erythema annulare centrifugum; Cutaneous focal mucinosis; Lentigines; Spiny follicular hyperkeratosis

IgA, Immunoglobulin A.

Table 2. Adverse systemic reactions associated with ustekinumab

1. Systemic allergic reactions to the administration of treatment	Flushing, anaphylactoid reaction, nausea, vomiting, blurred vision and/or confusion, dizziness, difficulty in breathing
2. Whole body (general disorders)	Asthenia, Flu-like symptoms, myalgia, anorexia, depression, sleep disturbance
3. Infections	Bacterial infections: latent tuberculosis reactivation, miliary tuberculosis, meningococcal meningitis, pneumonia, Clostridium difficile infection, Mycobacterium fortuitum ventriculoperitoneal shunt infection, perianal abscess, dental abscess, urinary tract infection, Staphylococcus aureus bacteremia with iliac artery endarteritis, Streptococcal sepsis; Viral infections: HSV-2 meningitis, Varicella zoster virus meningitis, acute hepatitis B, HBV reactivation, HCV reactivation, herpes simplex virus encephalitis, nasopharyngitis, Respiratory tract infections; Fungal infection: mycotic oesophagitis; Parasitic infections: Amoebic liver abscess, Ocular toxoplasmosis, severe acute toxoplasmosis
4. Neoplasia	Anal adenocarcinoma, cancer of anal fistula, endometrial cancer, esophageal cancer, hepatocellular carcinoma, pancreatic adenocarcinoma Malignant peritoneal mesothelioma, Gastric Mucosa-Associated Lymphoid Tissue Lymphoma, Exacerbation of Hodgkin's lymphoma, chronic lymphocytic leukaemia, multiple myeloma, papillary thyroid cancer, breast cancer
5. Cardiovascular events	Hypertension, congestive heart failure, dilated cardiomyopathy, unstable angina, Vasculitis, central retinal vein and artery occlusion
6. Gastrointestinal events / Hepatobiliary events	Acute hepatitis, elevated alanine transferase levels, fatty liver infiltration, diverticulitis, retroperitoneal fibrosis, pancreatitis
7. Musculoskeletal events	Paradoxical psoriatic arthritis, arthralgia, multifocal myositis, polymyositis, myasthenia gravis
8. Renal adverse events	Lupus nephritis, new-onset autoantibody-mediated nephritis, nephrotic syndrome, IgA nephropathy, focal segmental glomerulosclerosis
9. Nervous system events	Headache, neuropathic pain, memory loss, parkinsonism, benign intracranial hypertension, posterior reversible encephalopathy syndrome, demyelination, limbic encephalitis, Facial palsy, reversible cerebral vasoconstriction syndrome, ischaemic stroke, Guillain–Barré syndrome, peripheral neuropathy
10. Respiratory adverse events	Noninfectious pneumonia, bronchospasm crisis, pneumothorax, sarcoidosis
11. Urogenital and obstetric events	Urolithiasis; Epididymo-orchitis, erectile dysfunction; Foetal death and miscarriage
12. Other systemic events	Monoclonal gammopathy of undetermined significance; Autoimmune thyroiditis

HBV, hepatitis B virus; HCV, hepatitis C virus; HSV-2, herpes simplex virus-2.

considered a major scientific breakthrough as the first non-TNF- α inhibiting biologic that has been proven effective in the disease, paving the way for its approval for moderate-to-severe psoriasis since 2009. Although off-label, new clinical data and various indications in adults and children have emerged for ustekinumab in recent years.

In pediatric dermatology, patients seem to tolerate ustekinumab with minimal side effects, according to the CADMUS trials and various published case reports. However, as with adults, a thorough history, physical examination, and biologic workup with careful assessment for active infections and screening for active or latent tuberculosis, normal cardiovascular and neurological functions, and absence of malignancy, complete blood count, and metabolic profile are a minimum before the start of ustekinumab. Subsequently, regular follow-up investigations should be conducted.

Finally, the data discussed in this holistic review is mainly based on numerous pediatric case series. Unfortunately, the existing literature does not indicate definite safety and efficacy in children; more clinical and prospective data are needed to strengthen these conclusions.

Acknowledgments

None.

Funding

None.

Conflict of interest

Dr. Hakim Rahmoune has been an editorial board member of *Journal of Exploratory Research in Pharmacology* since June 2017. The authors have no other conflicts of interest to declare.

Author contributions

Contributed to study concept and design (ASC, NB, and HR), acquisition of the data (ASC), data analysis (ASC), drafting of the manuscript (ASC), critical revision of the manuscript (HR and NB), and supervision (ASC and HR).

References

- [1] Benson JM, Peritt D, Scallon BJ, Heavner GA, Shealy DJ, Giles-Komar JM, *et al*. Discovery and mechanism of ustekinumab: a human monoclonal antibody targeting interleukin-12 and interleukin-23 for treatment of immune-mediated disorders. *MAbs* 2011;3(6):535–545. doi:10.4161/mabs.3.6.17815, PMID:22123062.
- [2] Leonardi CL, Kimball AB, Papp KA, Yeilding N, Guzzo C, Wang Y, *et al*. PHOENIX 1 study investigators. Efficacy and safety of ustekinumab, a human interleukin-12/23 monoclonal antibody, in patients with psoriasis: 76-week results from a randomised, double-blind, placebo-controlled trial (PHOENIX 1). *Lancet* 2008;371(9625):1665–1674. doi: 10.1016/S0140-6736(08)60725-4, PMID:18486739.
- [3] Papp KA, Langley RG, Lebwohl M, Krueger GG, Szapary P, Yeilding N, *et al*. PHOENIX 2 study investigators. Efficacy and safety of ustekinumab, a human interleukin-12/23 monoclonal antibody, in patients with psoriasis: 52-week results from a randomised, double-blind, placebo-controlled trial (PHOENIX 2). *Lancet* 2008;371(9625):1675–1684. doi:10.1016/S0140-6736(08)60726-6, PMID:18486740.
- [4] Landells I, Marano C, Hsu MC, Li S, Zhu Y, Eichenfield LF, *et al*. Ustekinumab in adolescent patients age 12 to 17 years with moderate-to-severe plaque psoriasis: results of the randomized phase 3 CADMUS study. *J Am Acad Dermatol* 2015;73(4):594–603. doi:10.1016/j.jaad.2015.07.002, PMID:26259989.
- [5] Philipp S, Menter A, Nikkels AF, Barber K, Landells I, Eichenfield LF, *et al*. Ustekinumab for the treatment of moderate-to-severe plaque psoriasis in paediatric patients (≥ 6 to <12 years of age): efficacy, safety, pharmacokinetic and biomarker results from the open-label CADMUS Jr study. *Br J Dermatol* 2020;183(4):664–672. doi:10.1111/bjd.19018, PMID:32173852.
- [6] Kimmel GW, Lebwohl M. Psoriasis: Overview and diagnosis. In: Bhutani T, Liao W, Nakamura M (ed). *Evidence-Based Psoriasis*. Cham: Springer; 2018. doi:10.1007/978-3-319-90107-7_1.
- [7] Bonigen J, Phan A, Hadj-Rabia S, Boralévi F, Bursztejn AC, Bodemer C, *et al*. Impact of sex and age on the clinical and epidemiological aspects of childhood psoriasis: Data from a French cross-sectional multicentre study (in French). *Ann Dermatol Venerol* 2016;143(5):354–363. doi:10.1016/j.annder.2016.02.006, PMID:26969479.
- [8] Rendon A, Schäkel K. Psoriasis pathogenesis and treatment. *Int J Mol Sci* 2019;20(6):E1475. doi:10.3390/ijms20061475, PMID:30909615.
- [9] Jeon C, Sekhon S, Yan D, Afifi L, Nakamura M, Bhutani T. Monoclonal antibodies inhibiting IL-12, -23, and -17 for the treatment of psoriasis. *Hum Vaccin Immunother* 2017;13(10):2247–2259. doi:10.1080/21645515.2017.1356498, PMID:28825875.
- [10] Kim JC, Kim SM, Soh BW, Lee ES. Comparison of cytokine expression in paediatric and adult psoriatic skin. *Acta Derm Venereol* 2020;100(4):adv00058. doi:10.2340/00015555-3396, PMID:31930425.
- [11] Zhang L, Li Y, Yang X, Wei J, Zhou S, Zhao Z, *et al*. Characterization of Th17 and FoxP3(+) Treg cells in paediatric psoriasis patients. *Scand J Immunol* 2016;83(3):174–180. doi:10.1111/sji.12404, PMID:26679087.
- [12] Megna M, Napolitano M, Balato A, Scalvenzi M, Cirillo T, Gallo L, Ayala F, *et al*. Psoriasis in children: a review. *Curr Pediatr Rev* 2015;11(1):10–26. doi:10.2174/1573400511666150504125456, PMID:25938378.
- [13] Gautam M, Shukla R. Biologics in pediatric dermatology. *Indian J Paediatr Dermatol* 2021;22:107–117. doi:10.4103/ijpd.ijpd_24_21.
- [14] psoriasis.org [Internet]. FDA Approves Stelara® for Pediatric Psoriasis Patients. Portland: National Psoriasis Foundation (NPF). Available from: <https://www.psoriasis.org/advance/fda-approves-stelara-for-pediatric-psoriasis-patients/>. Accessed July 18, 2022.
- [15] Paller AS, Seyger MMB, Alejandro Magariños G, Bagel J, Pinter A, Cather J, *et al*. IXORA-PEDS study group. Efficacy and safety of ixekizumab in a phase III, randomized, double-blind, placebo-controlled study in paediatric patients with moderate-to-severe plaque psoriasis (IXORA-PEDS). *Br J Dermatol* 2020;183(2):231–241. doi:10.1111/bjd.19147, PMID:32316070.
- [16] Sun L, He C, Nair L, Yeung J, Egwuagu CE. Interleukin 12 (IL-12) family cytokines: Role in immune pathogenesis and treatment of CNS autoimmune disease. *Cytokine* 2015;75(2):249–255. doi:10.1016/j.cyto.2015.01.030, PMID:25796985.
- [17] Teng MW, Bowman EP, McElwee JJ, Smyth MJ, Casanova JL, Cooper AM, *et al*. IL-12 and IL-23 cytokines: from discovery to targeted therapies for immune-mediated inflammatory diseases. *Nat Med* 2015;21(7):719–729. doi:10.1038/nm.3895, PMID:26121196.
- [18] Wojkowska DW, Szpakowski P, Glabinski A. Interleukin 17A Promotes Lymphocytes Adhesion and Induces CCL2 and CXCL1 Release from Brain Endothelial Cells. *Int J Mol Sci* 2017;18(5):E1000. doi:10.3390/ijms18051000, PMID:28481289.
- [19] Young MS, Horn EJ, Cather JC. The ACCEPT study: ustekinumab versus etanercept in moderate-to-severe psoriasis patients. *Expert Rev Clin Immunol* 2011;7(1):9–13. doi:10.1586/eci.10.92, PMID:21162644.
- [20] Zitouni J, Beauchet A, Curmin R, Di Lernia V, Bursztejn AC, Mazereeuw-Hautier J, *et al*. Effectiveness and Safety of Adalimumab, Etanercept and Ustekinumab for Severe Psoriasis in Children Under 12 Years of Age: A French-Italian Daily Practice Cohort (BiPeJr). *Paediatr Drugs* 2022;24(3):281–292. doi:10.1007/s40272-022-00501-6, PMID:35397731.
- [21] Phan C, Beauchet A, Reguiat Z, Severino-Freire M, Mazereeuw-Hautier

- J, Bursztejn AC, *et al*. Switching biologics in children with psoriasis: Results from the BiPe cohort. *Pediatr Dermatol* 2022;39(1):35–41. doi:10.1111/pde.14845, PMID:34888920.
- [22] Ladha MA, Rankin BD, Adly M, Stevenson R, Luca NJ, Devani AR, *et al*. Real-world experience with ustekinumab for the treatment of plaque psoriasis in pediatric patients: A retrospective, single-center chart review. *J Am Acad Dermatol* 2022. doi:10.1016/j.jaad.2022.02.022, PMID:35192897.
- [23] Silverberg NB. Pediatric psoriasis: an update. *Ther Clin Risk Manag* 2009;5:849–856. doi:10.2147/tcrm.s4908, PMID:19898649.
- [24] Gananandan K, Sacks B, Ewing I. Guttate psoriasis secondary to COVID-19. *BMJ Case Rep* 2020;13(8):e237367. doi:10.1136/bcr-2020-237367, PMID:32784237.
- [25] Fang R, Sun Q. Guttate Psoriasis. *Indian Pediatr* 2020;57(6):596–597. doi:10.1007/s13312-020-1880-0, PMID:32562412.
- [26] Pinson R, Sotoodian B, Fiorillo L. Psoriasis in children. *Psoriasis (Auckl)* 2016;6:121–129. doi:10.2147/PTT.S87650, PMID:29387599.
- [27] Napolitano M, Megna M, Balato A, Ayala F, Lembo S, Villani A, *et al*. Systemic Treatment of Pediatric Psoriasis: A Review. *Dermatol Ther (Heidelb)* 2016;6(2):125–142. doi:10.1007/s13555-016-0117-6, PMID:27085539.
- [28] Signa S, Campione E, Rusmini M, Chiesa S, Grossi A, Omenetti A, *et al*. Whole exome sequencing approach to childhood onset familial erythrodermic psoriasis unravels a novel mutation of CARD14 requiring unusual high doses of ustekinumab. *Pediatr Rheumatol Online J* 2019;17(1):38. doi:10.1186/s12969-019-0336-3, PMID:31286971.
- [29] Burden-Teh E, Thomas KS, Ratib S, Grindlay D, Adaji E, Murphy R. The epidemiology of childhood psoriasis: a scoping review. *Br J Dermatol* 2016;174(6):1242–1257. doi:10.1111/bjd.14507, PMID:26928555.
- [30] Robinson A, Van Voorhees AS, Hsu S, Korman NJ, Leibold MG, Bebo BF Jr, *et al*. Treatment of pustular psoriasis: from the Medical Board of the National Psoriasis Foundation. *J Am Acad Dermatol* 2012;67(2):279–288. doi:10.1016/j.jaad.2011.01.032, PMID:22609220.
- [31] Herlin T, Christiansen M, Jørgensen SE, Høst C, Glerup M, Veirum JE, *et al*. Long-term treatment with ustekinumab for generalized pustular psoriasis in a child with heterozygous mutation in the IL36RN and TYK2 gene. *Pediatr Rheumatol* 2019;17(Suppl 1):P1092. doi:10.1186/s12969-019-0313-x.
- [32] Habal N, Chen Y, Jordan C, Liu Y, Neal DCC, Stone D, *et al*. Pathogenesis study of infantile-onset, severe pustular psoriasis reveals a de novo mutation in CARD14 causing psoriasis which responds clinically to IL-12/23 blocking treatment with ustekinumab. *Arthritis Rheum* 2011;63(10):S116.
- [33] Roenneberg S, Biedermann T. Pityriasis rubra pilaris: algorithms for diagnosis and treatment. *J Eur Acad Dermatol Venereol* 2018;32(6):889–898. doi:10.1111/jdv.14761, PMID:29247481.
- [34] Craiglow BG, Boyden LM, Hu R, Virtanen M, Su J, Rodriguez G, *et al*. CARD14-associated papulosquamous eruption: A spectrum including features of psoriasis and pityriasis rubra pilaris. *J Am Acad Dermatol* 2018;79(3):487–494. doi:10.1016/j.jaad.2018.02.034, PMID:29477734.
- [35] Bonomo L, Raja A, Tan K, Guttman-Yassky E. Successful treatment of juvenile pityriasis rubra pilaris with ustekinumab in a 7-year-old girl. *JAAD Case Rep* 2018;4(2):206–210. doi:10.1016/j.jadcr.2017.09.010, PMID:29892668.
- [36] Provini LE, Stellar JJ, Stetzer MN, Nguyen PD, Jen M. Combination hyperbaric oxygen therapy and ustekinumab for severe hidradenitis suppurativa. *Pediatr Dermatol* 2019;36(3):381–383. doi:10.1111/pde.13775, PMID:30805965.
- [37] Goldburg SR, Strober BE, Payette MJ. Hidradenitis suppurativa: Epidemiology, clinical presentation, and pathogenesis. *J Am Acad Dermatol* 2020;82(5):1045–1058. doi:10.1016/j.jaad.2019.08.090, PMID:31604104.
- [38] Provini LE, Stellar JJ, Stetzer MN, Nguyen PD, Jen M. Combination hyperbaric oxygen therapy and ustekinumab for severe hidradenitis suppurativa. *Pediatr Dermatol* 2019;36(3):381–383. doi:10.1111/pde.13775, PMID:30805965.
- [39] Monsalvez V, Postigo C, Rivera R, Palencia S. Hidradenitis suppurativa and ulcerative colitis, difficult treatment to control both pathologies at the same time. *Exp Dermatol* 2019;28(Supplement 2):21.
- [40] Gilaberte Y, Pérez-Gilaberte JB, Poblador-Plou B, Bliker-Bueno K, Gimeno-Miguel A, Prados-Torres A. Prevalence and Comorbidity of Atopic Dermatitis in Children: A Large-Scale Population Study Based on Real-World Data. *J Clin Med* 2020;9(6):E1632. doi:10.3390/jcm9061632, PMID:32481591.
- [41] Waldman AR, Ahluwalia J, Udokoff J, Borok JF, Eichenfield LF. Atopic Dermatitis. *Pediatr Rev* 2018;39(4):180–193. doi:10.1542/pir.2016-0169, PMID:29610426.
- [42] Fernández-Antón Martínez MC, Alfageme Roldán F, Ciudad Blanco C, Suárez Fernández R. Ustekinumab in the treatment of severe atopic dermatitis: a preliminary report of our experience with 4 patients. *Actas Dermosifiliogr* 2014;105(3):312–313. doi:10.1016/j.adengl.2013.05.005, PMID:24657022.
- [43] Agusti-Mejias A, Messeguer F, García R, Febrer I. Severe refractory atopic dermatitis in an adolescent patient successfully treated with ustekinumab. *Ann Dermatol* 2013;25(3):368–370. doi:10.5021/ad.2013.25.3.368, PMID:24003284.
- [44] Wlodek C, Hewitt H, Kennedy CT. Use of ustekinumab for severe refractory atopic dermatitis in a young teenager. *Clin Exp Dermatol* 2016;41(6):625–627. doi:10.1111/ced.12847, PMID:27079289.
- [45] Pan Y, Xu L, Qiao J, Fang H. A systematic review of ustekinumab in the treatment of atopic dermatitis. *J Dermatolog Treat* 2018;29(6):539–541. doi:10.1080/09546634.2017.1406894, PMID:29164954.
- [46] Pourang A, Mesinkovska NA. New and Emerging Therapies for Alopecia Areata. *Drugs* 2020;80(7):635–646. doi:10.1007/s40265-020-01293-0, PMID:32323220.
- [47] Aleisa A, Lim Y, Gordon S, Her MJ, Zancanaro P, Abudu M, *et al*. Response to ustekinumab in three pediatric patients with alopecia areata. *Pediatr Dermatol* 2019;36(1):e44–e45. doi:10.1111/pde.13699, PMID:30338558.
- [48] Ortolan LS, Kim SR, Crotts S, Liu LY, Craiglow BG, Wambier C, *et al*. IL-12/IL-23 neutralization is ineffective for alopecia areata in mice and humans. *J Allergy Clin Immunol* 2019;144(6):1731–1734.e1. doi:10.1016/j.jaci.2019.08.014, PMID:31470035.
- [49] Bonekamp N, Caorsi R, Viglizzo GM, Graaf M, Minoia F, Grossi A, *et al*. High-dose ustekinumab for severe childhood deficiency of interleukin-36 receptor antagonist (DITRA). *Ann Rheum Dis* 2018;77(8):1241–1243. doi:10.1136/annrheumdis-2017-211805, PMID:28866646.
- [50] Cherqaoui B Jr, Rossi-Semerano L, Piram M, Koné-Paut I. Standard dose of Ustekinumab for childhood-onset deficiency of interleukin-36 receptor antagonist. *Ann Rheum Dis* 2018;77(12):e88. doi:10.1136/annrheumdis-2017-212793, PMID:29259046.
- [51] Poulton C, Gratton D, Murray K, Baynam G, Halbert A. Autosomal recessive congenital ichthyosis due to homozygous variants in NIPAL4 with a dramatic response to ustekinumab. *Pediatr Dermatol* 2019;36(6):1002–1003. doi:10.1111/pde.13995, PMID:31532840.
- [52] Volc S, Maier L, Gritsch A, Aichelburg MC, Volc-Platzer B. Successful treatment of Netherton syndrome with ustekinumab in a 15-year-old girl. *Br J Dermatol* 2020;183(1):165–167. doi:10.1111/bjd.18892, PMID:31977080.
- [53] Paller AS, Czarnowicki T, Renert-Yuval Y, Holland K, Huynh T, Sadlier M, *et al*. The spectrum of manifestations in desmoplakin gene (DSP) spectrin repeat 6 domain mutations: Immunophenotyping and response to ustekinumab. *J Am Acad Dermatol* 2018;78(3):498–505.e2. doi:10.1016/j.jaad.2017.10.026, PMID:29066275.
- [54] Kellen R, Silverberg NB, Leibold M. Efficacy and safety of ustekinumab in adolescents. *Pediatric Health Med Ther* 2016;7:109–120. doi:10.2147/PHMT.S75836, PMID:29388600.
- [55] Rolston VS, Kimmel J, Popov V, Bosworth BP, Hudesman D, Malter LB, *et al*. Ustekinumab Does Not Increase Risk of Adverse Events: A Meta-Analysis of Randomized Controlled Trials. *Dig Dis Sci* 2021;66(5):1631–1638. doi:10.1007/s10620-020-06344-w, PMID:32445049.
- [56] Li X, Andersen KM, Chang HY, Curtis JR, Alexander GC. Comparative risk of serious infections among real-world users of biologics for psoriasis or psoriatic arthritis. *Ann Rheum Dis* 2020;79(2):285–291. doi:10.1136/annrheumdis-2019-216102, PMID:31672774.
- [57] Papp K, Gottlieb AB, Naldi L, Pariser D, Ho V, Goyal K, *et al*. Safety Surveillance for Ustekinumab and Other Psoriasis Treatments from the Psoriasis Longitudinal Assessment and Registry (PSOLAR). *J Drugs Dermatol* 2015;14(7):706–714. PMID:26151787.